



## The AP chest X-ray

The critically ill patient—special considerations

---

---

---

---

---

---

### What will I gain from this video?

At the end of the video, you will know what specific things to look for on a chest X-ray of a critically ill patient.

---

---

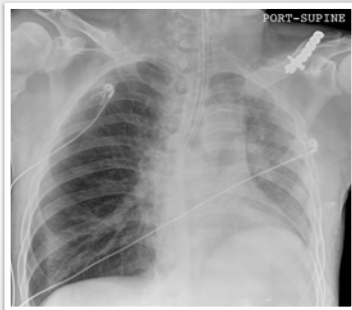
---

---

---

---

### Lines, tubes, and other devices



---

---

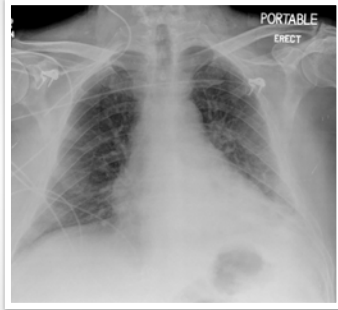
---

---

---

---

**Lines, tubes, and other devices**



---

---

---

---

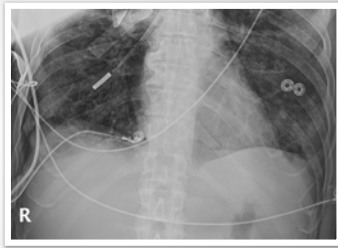---

---

---

---

**Lines, tubes, and other devices**



---

---

---

---

---

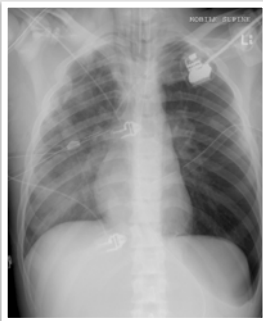
---

---

---

**Barotrauma**

Deep sulcus sign



---

---

---

---

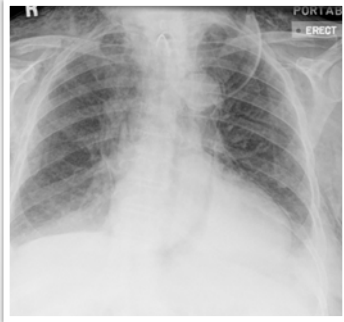---

---

---

---

**Barotrauma**



---

---

---

---

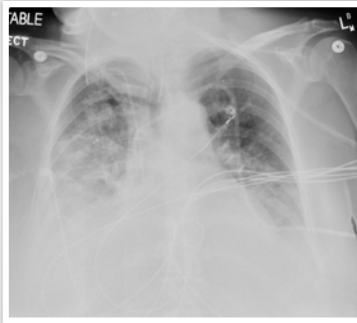
---

---

---

---

**Aspiration  
pneumonitis**



---

---

---

---

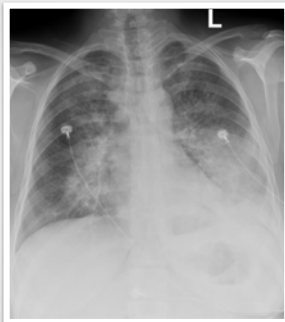---

---

---

---

**Aspiration  
pneumonitis**



---

---

---

---

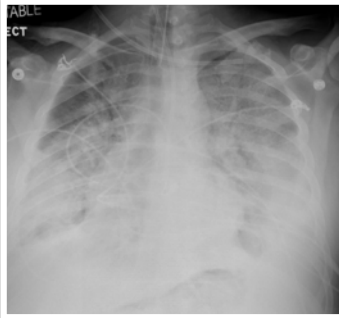
---

---

---

---

ARDS



---

---

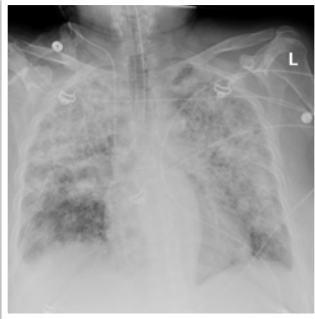---

---

---

---

ARDS



---

---

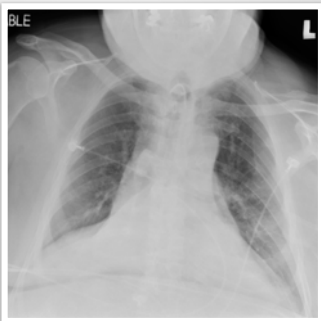---

---

---

---

Collapse



---

---

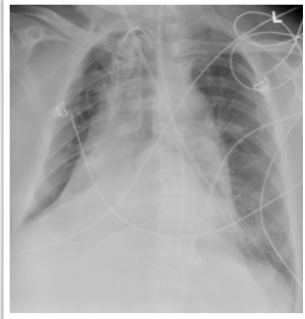
---

---

---

---

**Collapse**



---

---

---

---

---

---

Need careful attention to previous—look for improvement or disease progression.

Need careful attention to line and tube position.

Careful attention to barotrauma.

---

---

---

---

---

---